

An Interdisciplinary Approach for Management of Missing Canines with Implant Supported Cantilevered Prosthesis

Dr. Anugya Karanjit,¹ Dr. Shaili Pradhan,¹ Dr. Ranjita Shrestha Gorkhali,¹
Dr. Pramod Kumar Koirala,¹ Dr. Suchana Adhikari¹

¹Periodontology and Oral Implantology unit, Department of Dental Surgery, Bir Hospital, National Academy of Medical Sciences, Mahabouddha, Kathmandu, Nepal.

ABSTRACT

Missing tooth in the anterior region of the maxilla lies in aesthetic zone and create quite noticeable discrepancies. With a paradigm shift in the patient expectations towards functional as well as aesthetically appealing replacements for edentulism, the implant based oral rehabilitation has emerged as a sole winner in fulfilling all aspects of patient needs. Interdisciplinary team treatment planning is a paramount approach for achieving optimal final aesthetics. This article aims to present a case report of replacement of bilaterally missing maxillary canine and lateral incisors with cantilever prosthesis using an interdisciplinary approach.

Keywords: Cantilever; dental implant; interdisciplinary; missing teeth.

INTRODUCTION

An issue that frequently presents to clinicians is missing anterior teeth.¹ Incidence of impacted maxillary canine range from 0.92-3.58%² and maxillary lateral incisor 1-5%.³ Osseointegrated implants are the most biologically conservative and commonly used option for replacing missing teeth provided the available space is enough for implant placement.¹ Cantilever fixed partial denture is a fixed restoration which has one or more abutments at one end while the other end is unsupported which can be successfully given in anterior quadrant.⁴ Regardless of the type of replacement, interdisciplinary treatment considerations are required for restorative excellence.⁵

CASE REPORT

A 25-year-old female reported to Periodontology and Oral Implantology unit, Bir Hospital with the chief complaint of replacement of missing teeth. She was undergoing active orthodontic treatment for past two years. No specific medical history was elicited. No any abnormality was present during extra oral examination. On oral examination, the patient had bilateral missing permanent maxillary canines and lateral incisors with

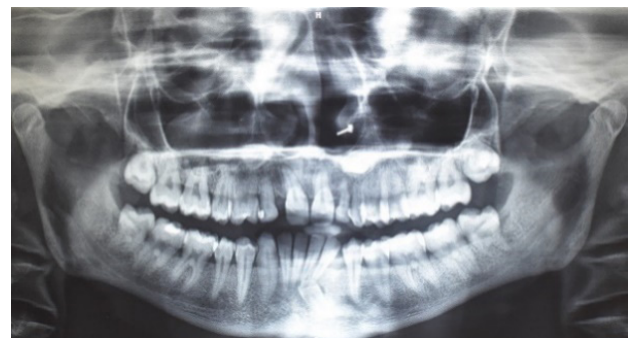

Figure 1: Pre-operative orthopantomogram.

retained deciduous maxillary lateral incisors and deciduous maxillary left canine.

Maxillary arch presented with spacing between 11 and 52 and 21 and 22. Similarly, mandibular arch presented with mild spacing on anterior teeth with missing left mandibular canine. Preliminary investigations including cone beam computed tomography and routine blood investigations were done. Based on the history, clinical and radiographic examination, diagnosis of impacted 13, 23, 33 with retained deciduous teeth w.r.t 52,53,63 was made. Interdisciplinary approach was discussed which included patient and clinicians from orthodontic, surgery, prosthodontic and periodontic units.

Tentative treatment plan was agreed upon as a team which included oral prophylaxis, followed by extraction of deciduous teeth. Orthodontic therapy would be carried out for alignment and achievement of sufficient space for placement of dental implant and prosthesis followed by Supportive periodontal treatment.

Correspondence

Dr. Anugya Karanjit

Email id: karanjitanugya@gmail.com



Citation

Karanji A, Pradhan S, Gorkhali RS, Koirala PK, Adhikari S. An Interdisciplinary Approach for Management of Missing Canines with Implant Supported Cantilevered Prosthesis. J Nepal Soc Perio Oral Implantol. 2022 Jul-Dec;6(12):91-4.

This is an open access journal, and articles are distributed under the terms of the Creative Commons Attribution CC BY 4.0 Licence.

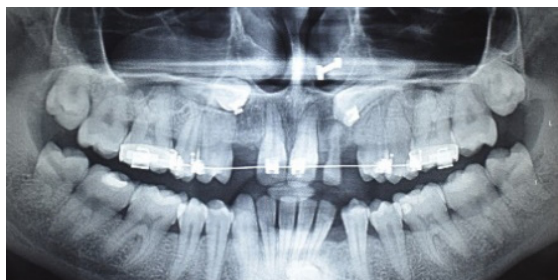

Figure 2: During active orthodontic treatment.

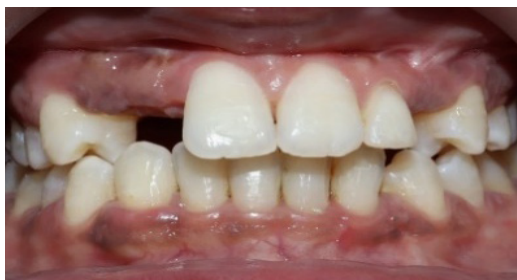

Figure 3: Space gained between 14 and 11 for implant placement after orthodontic therapy.

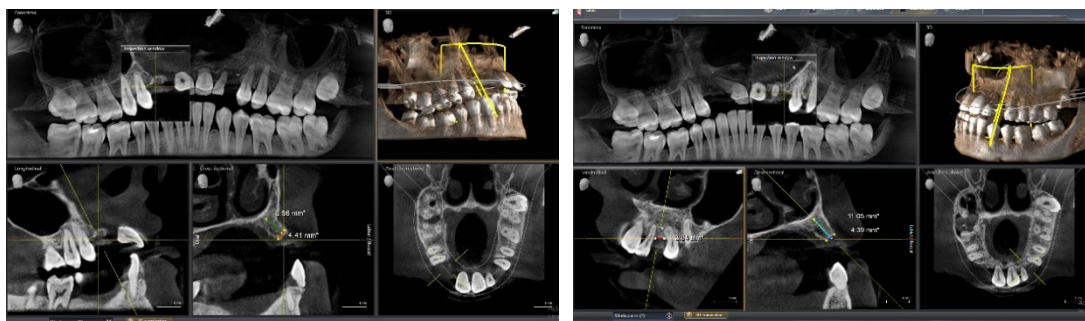


Figure 4: Segmental CBCT showing a) maxillary right canine region, b) maxillary left canine region

Impacted canines had to be surgically extracted as it could not be orthodontically aligned. After completion of orthodontic treatment, the patient was referred to the periodontology unit for consultation on implant therapy. Orthodontic treatment was able to provide adequate space in the maxillary right canine region. However, on the left maxillary canine region, it was able to provide a mesio-distal space of only 3.94 mm with slight mesial tilting of root of maxillary left first premolar.

Therefore, the choice was made to place a single dental implant (3.5 * 10mm) on maxillary right canine and provide a cantilever bridge on maxillary right lateral

incisor. Similarly, maxillary left canine was decided to be restored with cantilever fixed partial denture using single premolar abutment.

Under all aseptic condition, infiltration of local anesthesia with 1:200000 adrenaline was administered and crestal incision was given and full thickness flap was raised. 2mm pilot drill was used to the required full depth and no sequential drill was used as the proposed implant (Bredent Narrow-sky) diameter was 3.5 mm. By maintaining torque at 35N, using motor driven implant hand piece with profuse irrigation with normal saline, implant fixture was inserted into the prepared site.

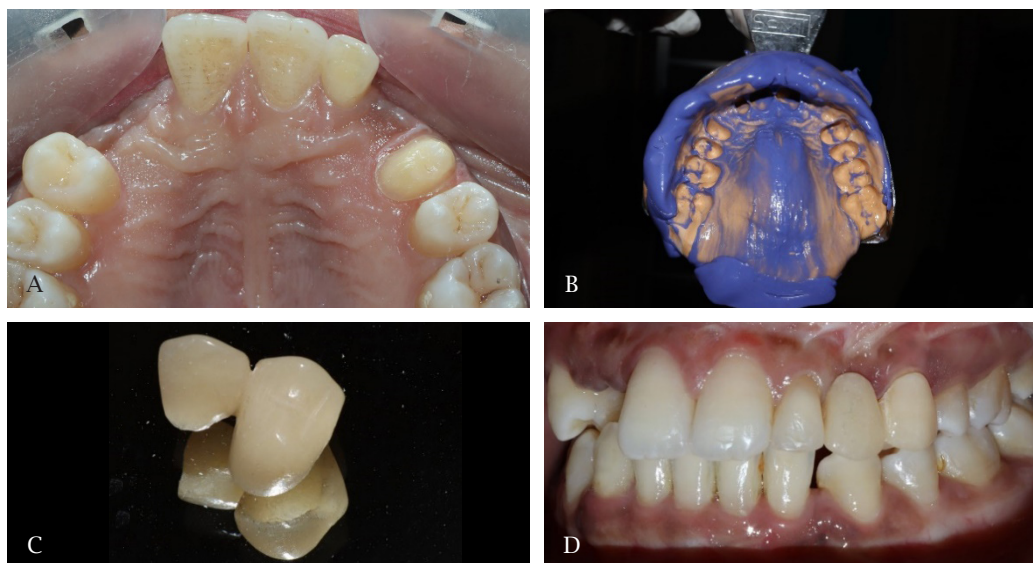


Figure 5: A) Tooth preparation on maxillary left first premolar, B) Impression was made using putty wash technique, C) Cantilever fixed partial bridge D) Post-cementation of prosthesis w.r.t 23 and 24.

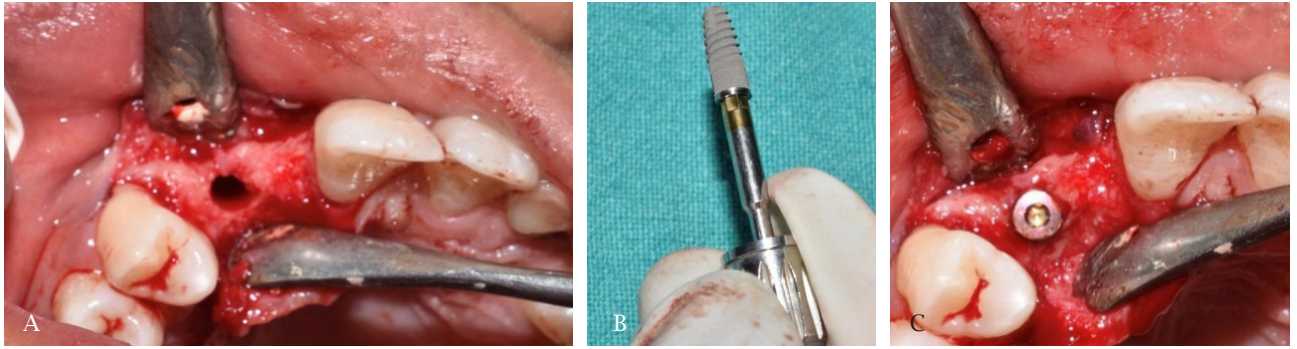


Figure 6: A) Osteotomy site for implant placement, B) Dental implant of size 3.5 * 10mm,0 C) After placement of implant fixture with Coverscrew.

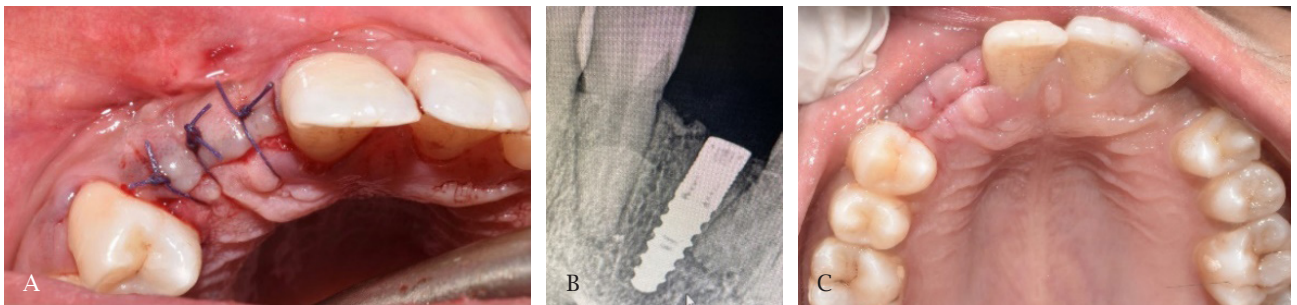


Figure 7: A) Primary closure of flap using interrupted suturing, B) Post-operative radiographic examination using IOPAR, C) 1 week post-operative healing.

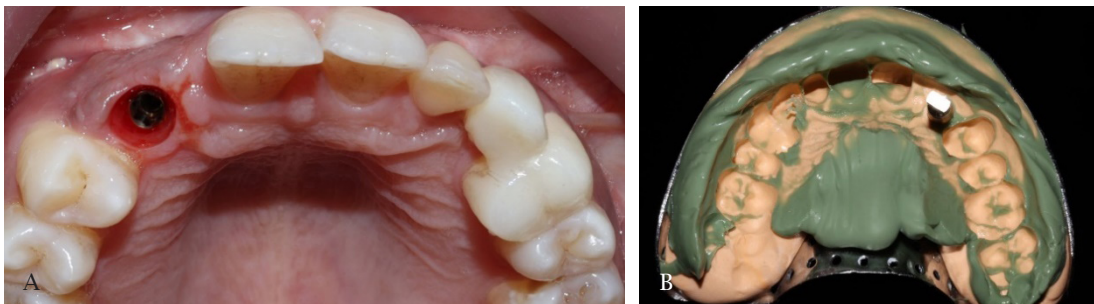


Figure 8: A) Gingival cuff after placement of healing abutment, B) Impression was with open tray technique.

Primary closure of flap was obtained with interrupted type resorbable sutures. Radiographic examination was done post-operatively. Amoxicillin (500 mg) was prescribed every 8 hours, and the treatment continued for 5-7 days. Chlorhexidine mouthwash (0.2% solution) was prescribed for two weeks. Additionally, patients were prescribed Acetaminophen plus Ibuprofen.

After 4 months under sterile conditions, healing abutment was placed with hex screw driver on the

implant. Two weeks later impressions were made with open tray technique. Shade selection was done using VITA Classic Shade guide. Healing abutments were replaced until prosthesis was manufactured. After a week, the healing abutments were removed and replaced by final abutments onto which zirconia crown with cantilevered prosthesis was placed using Hybrid (cement plus screw retained) technique. The patient was satisfied with the aesthetic and functional outcome. sal view.

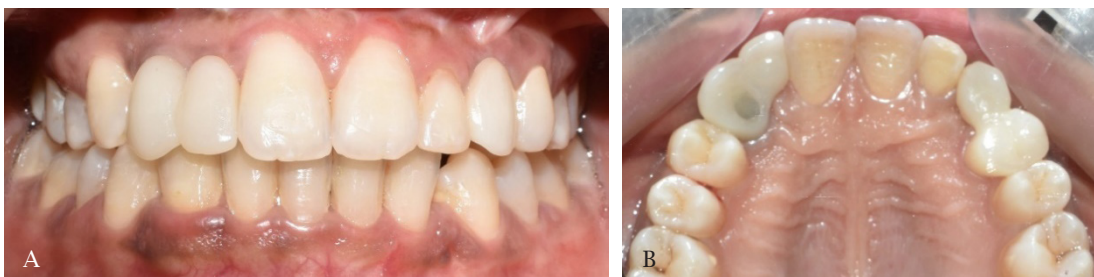

Figure 9: Final prostheses A) front view, B) occlusal view.

DISCUSSION

Interdisciplinary approach to optimize aesthetics and longevity are frequently needed in patients with missing teeth.¹ A thorough diagnosis and treatment plan must precede orthodontic therapy. Dental implants provide promising treatment options for the replacement of missing teeth. Advantages include preservation of adjacent natural tooth structure, alveolar ridge and achievement of optimal aesthetics and restorative results.⁶

The limitations includes inadequate available space, inadequate alveolar ridge thickness and inadequate alveolar bone support for gingival papilla.⁷ According to Carl E Mish, minimum of 1.0 mm bone should be present around the implant.⁸ So, by placing narrow diameter implant of 3.5mm, we preserve not only the remaining alveolar bone from resorption but also helps in achieving optimal aesthetics.

This case is slight different from conventional guidance regarding the use of cantilever fixed partial dentures, which suggests using two abutments. Particularly when replacing a maxillary canine the first option would be to utilize a single-tooth implant. The second option would likely be a conventional fixed partial denture utilizing the adjacent abutment teeth, possibly using double

abutments. Due to the patient's existing occlusion, personal preferences, a third option was used for this patient —cantilever fixed partial denture utilizing maxillary first premolars as the lone abutments. Cantilevered bridge is the second most conservative option, followed by full-coverage bridge.³

A systematic review of cantilever fixed partial dentures reported 18.2 % failure rate at 10 years, as compared to 10.9% with use of a conventional fixed partial denture.⁹ The most frequent complication was loss of retention, with the second being fracture of the restorative material. There are occasions, however, when complicated medical history or financial constraints make a cantilever fixed partial denture a reasonable option, as opposed to implant or conventional fixed partial denture.

SUMMARY

Effective treatment planning is crucial to successful outcomes. Dental implants offer a predictable solution to replace missing teeth, provided there is enough available space. Interdisciplinary team treatment planning is emphasized as a requirement for achieving function and aesthetics.

Conflict of Interest: None.

REFERENCES

1. Planning OT. Congenitally missing maxillary lateral incisors and orthodontic treatment considerations for the single-tooth implant. *J can dent assoc.* 2001;67:25-8.
2. Shah RM, Ma B, TF V. Studies of permanent tooth anomalies in 7,886 canadian individuals.I:Impacted Teeth. 1978 Jun;44(6):262-4.
3. Azzaldeen A, Nikos K, Georgos C, Abu-Hussein M. Unilateral Maxillary Lateral Incisor Agenesis with Mini Implant Prostheses: A Case Report. *Dent Implants Dentures.* 2016;1:106-10.
4. Sharma A, Rahul GR, Poduval ST, Shetty K. Assessment of various factors for feasibility of fixed cantilever bridge: A review study. *International Scholarly Research Notices.* 2012 Mar;2012:259891.
5. Muhamad AH, Azzaldeen A, Nezar W, Mohammed Z. Congenitally Missing Lateral Incisor with Orthodontics, Bone Grafting and Single-Tooth Implant: A Case Report. *J Dent Med Sci.* 2015;14(4):124-30.
6. Valle AL, Lorenzoni FC, Martins LM, Valle CV, Henriques JF, Almeida AL, Pegoraro LF. A multidisciplinary approach for the management of hypodontia: case report. *J Applied Oral Sci.* 2011;19:544-8.
7. Bishop K, Addy L, Knox J. Modern restorative management of patients with congenitally missing teeth: 4. The role of implants. *Dent Update.* 2007 Mar 2;34(2):79-84.
8. Misch CE, Perel ML, Wang HL, Sammartino G, Galindo-Moreno P, Trisi P, Steigmann M, Rebaudi A, Palti A, Pikos MA, Schwartz-Arad D. Implant success, survival, and failure: the International Congress of Oral Implantologists (ICOI) pisa consensus conference. *Implant Dent.* 2008 Mar 1;17(1):5-15.
9. Pjetursson BE, Tan K, Lang NP, Brägger U, Egger M, Zwahlen M. A systematic review of the survival and complication rates of fixed partial dentures (FPDs) after an observation period of at least 5 years: I. Implant-supported FPDs. *Clin Oral Implants Res.* 2004 Dec;15(6):625-42.